
NEUROTROPHIC KERATITIS TREATMENT AND MANAGEMENT, UTILIZING DEHYDRATED AMNIOTIC MEMBRANE

INTRODUCTION

Amniotic membrane grafts have been shown to provide a significant benefit in treating corneal and conjunctival disease in the optometric office. As we know, there are now a wide variety of options available in terms of manufacturers of amniotic tissue, however there are some that stand out among the pack. In the past, I had only used cryopreserved amniotic membranes and was unfamiliar with the dehydrated options. Below is a case summary of my recent patient's findings and why I now am a believer in the efficacy of dehydrated amniotic tissue from Atlas Ocular.

CASE SUMMARY

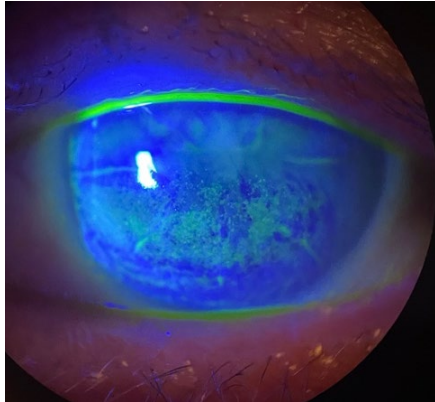
The patient was a 61-year-old male with a history radial keratometry surgery, and recalcitrant dry eye that was exacerbated by decreased tear production. He complained of sore eyes that never improved even with several different dry eye treatments. His best corrected acuity was 20/30 OD and 20/50 OS, though the refraction was difficult due to fluctuations in his ocular surface. Past treatments included copious lubrication and a myriad of topical immunosuppressants, including steroids and cyclosporine emulsion. Interestingly, his mild discomfort did not match the severity of his corneal findings. Therefore, corneal sensitivity testing with a cotton wisp was initiated and was decreased centrally and in all four corneal quadrants. As such, a diagnosis of neurotrophic keratopathy was confirmed.

TREATMENT PLAN

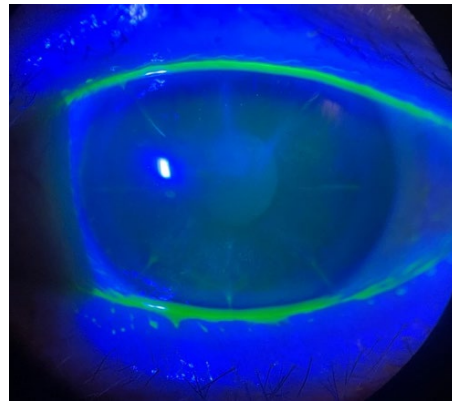
After reviewing treatment options with the patient, we elected to proceed with placement of The Apollo Amniotic Membrane from Atlas Ocular, first inserting the membrane into his worse seeing eye (OS) with a bandage contact lens. He returned in one week for removal of the contact lens and corneal evaluation, at which time his corneal epithelium had re-epithelialized with only trace punctate defects remaining. His best corrected visual acuity was now 20/20⁻² in the OS. On this visit, a second Apollo amniotic membrane was also placed in the right eye with a bandage lens. During the one week follow up exam the same impressive results were obtained; he had minimal corneal staining, improved acuity, and an increase in ocular comfort. I requested he start lubrication with Systane Hydration PF moving forward and follow up one month after the procedure.

POST-PLACEMENT OBSERVATIONS

At the one-month progress exam his corneas showed complete re-epithelization and no signs of punctate epithelial erosions. Increased corneal sensitivity was confirmed with cotton wisp testing, and most importantly, the patient was happy with the comfort and clarity of his vision.



Day of treatment/membrane placement w/BCL
(left eye)



Day of BCL removal (left eye)

Dr. Erick Henderson

Dr. Erick Henderson practices full scope optometry with an emphasis on specialty contact lenses and medical eye care. He received a Doctorate of Optometry from Southern College of Optometry in Memphis, TN, graduating with multiple honors recognizing his leadership and academic performance.

Dr. Henderson is an Education Consultant for Alcon Laboratories and Valley Contax. In these roles he travels the country to visit optometry institutions and participate in events teaching students and other optometrists about the latest advancements in eye care.

He has been published in the Journal of Global Health on the topic of eye care needs of rural Kenyans. He currently serves on the board of directors for the Lamu Center of Preventative Health in Lamu, Kenya and remains locally and internationally providing services to those who have little to no access to eye care

Dr. Henderson is not affiliated with, nor is he a paid consultant for Atlas Ocular.

